


Hybrid AF CONVERGE

Physician Case Study: Dr. Steinberg



Jonathan S. Steinberg, MD

Director, SMG Arrhythmia Center

Summit Medical Group

Professor of Medicine (adj)

*University of Rochester School
of Medicine*

*Core Professor of Cardiology
and Internal Medicine*

*Hackensack Meridian School
of Medicine*

Patient: 54 year-old male with no prior cardiovascular condition.

Patient History

About 10 years ago, while walking uphill, the patient had sudden onset of severe dyspnea and palpitations with mild diaphoresis. Because the symptoms recurred over several weeks, he saw a cardiologist and received a diagnosis of persistent atrial fibrillation (AF) with rapid ventricular rate of 110. Echocardiogram and stress test were unremarkable. He was started on diltiazem.

A few months later, after anticoagulation with warfarin, he underwent transesophageal echocardiogram and external cardioversion, which restored normal sinus rhythm (NSR).

For a few weeks he was completely asymptomatic, but then persistent AF and symptoms returned. Another cardioversion was contemplated, but instead he was prescribed amiodarone. He transiently returned to NSR but after few months, persistent AF once again recurred, and amiodarone was discontinued.

Further efforts at rhythm control were abandoned and the AF continued for the next decade. Warfarin was replaced with apixaban. The previously described symptoms continued intermittently.

The patient was seen in consultation early summer 2019. An ECG revealed AF with a ventricular rate in the 90s. An echo revealed normal left ventricular size and function, mild left atrial (LA) enlargement, and mild regurgitation of both mitral and tricuspid valves. A hybrid ablation was planned given his longstanding persistent AF, young age, and severe chronic symptoms despite AF rate control.

Treatment

In July 2019 he underwent hybrid ablation. A minimally invasive Convergent procedure was performed via subxiphoid access, with 22 radiofrequency (RF) lesions placed on the LA posterior wall. A pericardial drain was placed, and the transvenous catheters were introduced into the LA via transseptal puncture. Cardioversion restored NSR but AF quickly recurred. A detailed voltage map was created, revealing residual signal in the pulmonary vein (PV) antral regions bilaterally as well as on the superior posterior wall (see Map #1). The bulk of the posterior wall was electrically silent. Endocardial RF lesions were placed at the PV antra, posteriorly and anteriorly, until isolation confirmed. An LA roof line was then constructed, resulting in abrupt posterior wall isolation. Adenosine challenge was performed, and PV and posterior wall isolation was consistent. Another cardioversion restored NSR, which was sustained. Repeat voltage mapping confirmed complete electrical silence in the targeted regions (see Map #2).

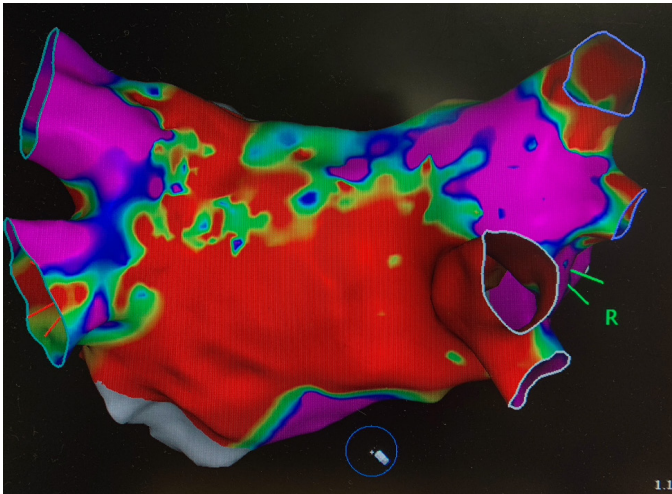
Hybrid AF CONVERGE Physician Case Study (continued)

The patient was hospitalized for 2 nights. Apixaban was resumed the night of the procedure. The pericardial drain was removed postop day #1. He remained in NSR throughout, experiencing mild pleuritic chest pain that gradually resolved.

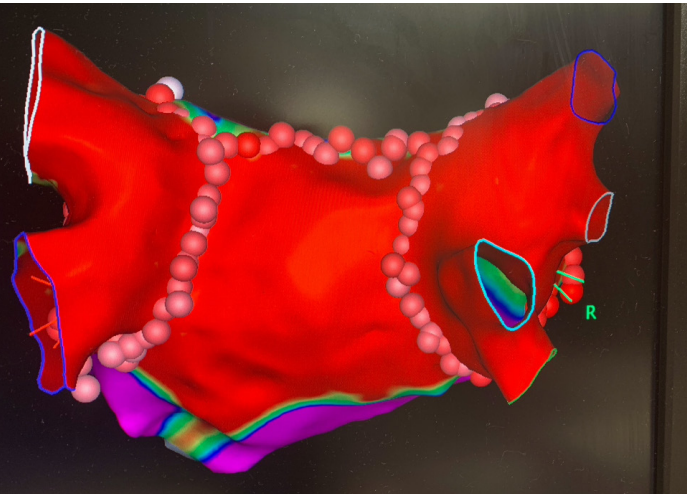
Outcome

The patient reported feeling very well for about a month, at which time he sensed resumption of AF with symptoms of chest “uneasiness” and generalized weakness. Symptoms continued for 5 days and then abruptly resolved, restoring well-being. Follow-up visits revealed that he has remained in NSR for over a year, and he is feeling very much improved. All anticoagulation and antiarrhythmics have been discontinued.

Map 1.



Map 2.



Note: Clinical results from case studies are not predictive of results in other cases. Results in other cases may vary.

EPI-Sense® Guided Coagulation System

U.S. Indications: The EPI-Sense Guided Coagulation System is intended for the treatment of symptomatic long-standing persistent atrial fibrillation (continuous atrial fibrillation greater than 12 months duration) when augmented in a hybrid procedure with an endocardial catheter listed in the instructions for use, in patients (1) who are refractory or intolerant to at least one Class I and/or III antiarrhythmic drug (AAD); and (2) in whom the expected benefit from rhythm control outweighs the potential known risks associated with a hybrid procedure such as delayed post-procedure inflammatory pericardial effusions. **Contraindications** include patients with Barrett's Esophagitis, left atrial thrombus, a systemic infection, active endocarditis, or a localized infection at the surgical site at the time of surgery. **Adverse Events:** Reported adverse events associated with epicardial ablation procedure may include, but are not limited to, the following: pericardial effusion/cardiac tamponade, pericarditis, excessive bleeding, phrenic nerve injury, stroke/TIA/neurologic complication. Please review the Instructions for Use for a complete listing of contraindications, warnings, precautions and potential adverse events located at the following AtriCure web address: <https://www.AtriCure.com/EPI-Sense-Coagulation-Device>. **Warnings:** Physicians should consider post-operative anti-inflammatory medication to decrease the potential for post-operative pericarditis, and/or delayed post-procedure inflammatory pericardial effusions. Physicians should consider post-procedural imaging (i.e. 1-3 weeks post-procedure) for detection of post-procedure inflammatory pericardial effusions. **Precautions:** Precautionary measures should be taken prior to considering treatment of patients: (1) Deemed to be high risk and who may not tolerate a potential delayed post-procedure inflammatory pericardial effusion. (2) Who may not be compliant with needed follow-ups to identify potential safety risks. To ensure patients undergoing treatment with the EPI-Sense device are well informed, the benefits, potential risks and procedural outcomes associated with the EPI-Sense Hybrid Convergent procedure should be discussed with the patient. Physicians should document accordingly in the medical record. Qualified operators are physicians authorized by their institution to perform surgical sub-xyphoid pericardial access. The coagulation devices should be used by physicians trained in the techniques of minimally invasive endoscopic surgical procedures and in the specific approach to be used. Operators should undergo training on the use of EPI-Sense device before performing the procedure. Safety and effectiveness of concomitant left atrial appendage closure was not evaluated in the CONVERGE study. Follow-up should be conducted at approximately 30 days post-procedure to monitor for signs of delayed onset pericarditis or pericardial effusion. **Rx Only.**